

Results of surgical treatment of mandible body fractures with own designed external fixator in two horses

BERNARD TUREK¹, KAMIL GÓRSKI¹, OLGA DREWNOWSKA¹,
TOMASZ SZARA², NATALIA KOZŁOWSKA¹

¹Department of Large Animal Diseases and Clinic, Institute of Veterinary Medicine, Warsaw University of Life Sciences, Nowoursynowska 166, 02-787 Warsaw, Poland

²Department of Morphological Sciences, Institute of Veterinary Medicine, Warsaw University of Life Sciences, Nowoursynowska 159, 02-787 Warsaw, Poland

Received 09.05.2022

Accepted 03.06.2022

Turek B., Górski K., Drewnowska O., Szara T., Kozłowska N.

Results of surgical treatment of mandible body fractures with own designed external fixator in two horses

Summary

Mandibular fractures are the most common among all skull fractures. Most of them are the result of blunt trauma resulting from hitting an obstacle, kicking by another horse, or falling after a jump. The majority of fractures are open and infected. Some of them are complicated, involving the molar or premolar teeth. Treatment of such fractures is challenging because results depend on stable bony union and functional integrity of the occlusal surface. Osteosyntheses were performed under general anesthesia. Complications included infection around one implant close to the fracture line and fistulation in case 2 created by a fractured tooth which had to be extracted. In spite of the mentioned problems, good results were achieved in both cases. Stabilization of unilateral mandibular fractures with our own design fixator which is minimally invasive and provides sufficient fixation to obtain good results. The use of the fixator has proved to be beneficial and has a number of advantages in the treatment of this kind of fracture.

Keywords: horse, osteosynthesis, mandible, external fixation

Mandibular fractures are the most common among all skull fractures (15). Most of them are the result of blunt trauma such as from collisions with a solid object, kicks from another horse, or falls after a jump (23). Other possible causes may be iatrogenic damage due to tooth extraction or improper dental treatment (7). Some of the fractures especially within the incisive region may be the result of biting metal components. Quite a rare group are pathological fractures resulting from an ongoing cancer process such as osteosarcoma or ossifying fibroma (2, 16). Mandibular fractures occur more frequently in young animals, probably due to their behavior and temperament (15). Clinical signs may include dysphagia, salivation, oral hemorrhage, mandibular swelling, and pain. According to the anatomical aspect, jaw fractures can be divided into the following groups: the rostral mandible (incisive region), interdental space, horizontal ramus, and the vertical part of the jaw. The vast majority of the fractures occur rostral to the cheek teeth (5, 11, 19). Only when the fracture is stable and food and water intake

are preserved, conservative treatment may be considered (12). Surgical intervention is recommended in the cases of unstable, dislocated, open, bilateral fractures, with advanced malocclusion (11, 12, 18, 23). The radiographic assessment has remained a crucial tool to determine the type, exact location of the fracture, and dental integrity. Computed tomography allows a better definition of caudal mandibular fractures. Most of these fractures are open, infected, and often associated with tooth involvement, which significantly complicates the treatment (19). The surgical fixation methods include screws, cerclage wiring, U-shaped metal splints, dynamic compression plates (DCP), limited contact plates (LCP), and external stabilization techniques (3, 5, 13, 19, 28). Choosing the right treatment depends on the location and configuration of the fracture. In complicated cases, it may be necessary to use the combination of internal and external fixation methods (1). External fixators are worth recommending, especially for open and infected fractures (9). Among them we can distinguish: unilateral (type 1), bilateral (type 2),

and a pinless external fixator (PEF). The latter was successfully used in the treatment of jaw fractures in horses and cattle (9, 14). In our study, we present the treatment of two horses with open fractures of the left mandibular body, with tooth involvement using an external unilateral fixator of novel design. Specific construction allows adjusting its position in three planes providing easy application during the treatment of the fractures. Oblique position of the pins inserted in the bone enhances stability (10, 25, 26). The purpose of this paper is to present a detailed technique, outcome, and complications associated with the use of an external fixator of author design in two horses.

Case presentation

Case 1. A 5-year-old show jumping Polish half-bred horse, mare, 550 kg of body weight was referred to the clinic due to an open, infected left-sided fracture of the mandibular body. A fracture of the jaw occurred when the horse fell at a jump. The horse was reluctant to eat and drink for ten days. Conservative treatment using a daily nonsteroidal anti-inflammatory drug (phenylbutazone 4.4 mg/kg P.O, q24h) resulted in a poor clinical outcome. On general examination, the patient presented fair condition and mild dehydration. Temperature and pulse were within the normal limits. A large deformation at the fracture site, painful in palpation with mild mandibular displacement to the left, and halitosis was present. Oral examination presented tooth 309 dislocated to the cheek side. Food material was embedded between the teeth. Radiography of this area was performed in the lateral and oblique projection. Radiographs revealed oblique, multiple fractures of the left mandibular body at the level of the first molar tooth (Fig. 1).



Fig. 1. Radiographic examination of the mandible in right ventral 60° left-dorsal lateral oblique view (Case 1) – visible fracture of the left body of the mandible with displaced tooth 309. Red arrows show 2 fracture lines. Visible widening of interdental space between 309-310 (black arrow)

Case 2. A 14-year-old half-bred horse, gelding, 350 kg of body weight was admitted to the clinic due to an open fracture of the left mandibular body. The fracture occurred as a result of a kick by another horse five days earlier. The horse was referred for surgical treatment at the request of the owner. Vitals signs were within normal ranges. Superficial skin damage was visible around the fracture. Saliva-

tion, quidding, and left-sided, ventrolateral mandibular swelling were visible. The horse was able to eat bran mash and drink water. In the examination of the oral cavity, the left lower dental arcade was disrupted. Complete fracture of tooth 308 was present, cranial and caudal parts were clearly separated by a fracture line. Halitosis occurred. The radiographic examination confirmed mandible fracture and complete longitudinal split in the frontal plane of tooth 308. The additional oblique crack of the rostral middle part of tooth 308 was present (Fig. 2).

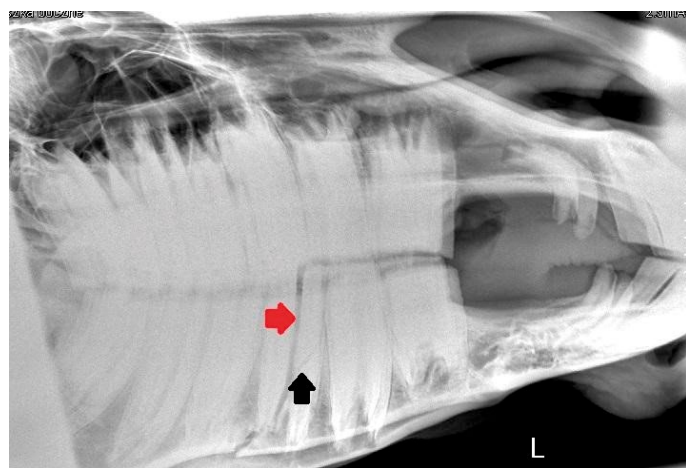


Fig. 2. Radiographic examination of the mandible, in late-lateral view (Case 2) – visible fracture of the body of the mandible and longitudinal split of 308 tooth (red arrow). The rostral part of the tooth fractured obliquely in the middle (black arrow)

Surgery. In both cases, fractures were stabilized with an external unilateral fixator of own design (Fig. 3). Pre-operative preparation was similar in both horses. Access to water was unlimited but the food was withheld. In Case 1, the horse received a total of 20 L of sodium chloride 0.9%, IV, the day before the surgery. Prior to the procedure intravenous flunixin meglumine (1.1 mg/kg, IV) and antibiotic in the form of a combination of procaine penicillin (8 mg/kg, IM) with streptomycin (8000 I.U./kg, IM) were given. The horses were operated under general anesthesia in lateral recumbency. The patients were sedated with detomidine (0.02 mg/kg) prior to anesthetic induction with diazepam (0.1 mg/kg) and ketamine (2.2 mg/kg). Intubation was done through the ventral nasal meatus to have a good view into the mouth to repose the fracture and tooth. Anesthesia was maintained using isoflurane (induction 5%, maintenance




Fig. 3. External fixator used in both cases. Note the oblique position of pins

2-3%). The oral cavity was rinsed with water and 0.12% solution of chlorhexidine gluconate. A catheter was used to lavage the fracture area with sterile saline. The skin was clipped and prepared aseptically. In Case 1, the dislocated and displaced tooth 309 was repositioned. The tooth was pushed by the dental forceps and placed in its proper position. Four stab incisions 7-8 mm in length were made through the skin, subcutaneous tissue, and periosteum on the lateral aspect of the mandibular body, two rostral and two caudal to the fracture line. Intraoperative radiography was performed before drilling to prevent damage to tooth roots. A 4.5 mm diameter drill bit was used to create holes in both cortical bones (TRS Modular Drive R Synthes, with the speed 500 rpm), sterile saline was applied to minimize the thermal damage. Self-threading Apex pins with 6 mm diameter were inserted into the drilled holes, which were then attached using special connectors with the booms mounted on the stabilizer's main rod. The connector was placed at a sufficient distance from the skin to allow for anticipated soft tissue edema. Radiographs were obtained to reveal the pin placement (Fig. 4). At the end of the surgery, the construction was cleansed of blood and debris. Sterile gauze was placed over incisions and around the fixator. Cotton padding was applied and covered with self-adherent bandaging tape.



Fig. 4. Radiograph of the mandible taken after the surgery (Case 2)

Postoperative treatment. The next day after surgery, the animals had no problems with food and water intake, and their appetite was maintained. Horses tolerated the presence of the fixator, mandibular motion was improved.

In the postoperative period, the same antibiotic was used as mentioned previously for a period of 10 days, administered once a day. Flunixin meglumine (1.1 mg/kg, q24 hours) was administered intravenously daily for 5 days after surgery. The initial bandage change took place on the 7th day after the procedure. Subsequent bandage changes were performed at intervals of two or three days as necessary. The bandage protected the construct quite effectively from damage or injury due to accidental impact or entrapment of

the frame on objects. Post-operative complications were observed in both cases. In the case 1 ten days after the surgery purulent discharge appeared around the pin applied in the rostral position close to the fracture line. Due to that complication, the pin had to be removed 2 weeks after the procedure. The fixator was disassembled in the stable 4 weeks after the surgery without the need for sedation or anesthesia. Fracture reduction and stabilization were good and resulted in proper healing. The horse returned to jumping three months after the end of treatment. In Case 2, problems with infection around one implant near the fracture line could be predictable. The affected pin had to be removed after 3 weeks. Removal of the whole fixator was done in the stable 7 weeks after the procedure in this case, due to the horse behavior, standing sedation was needed. Three weeks later, a fistula with purulent discharge appeared on the mandible. However, that did not interfere with feed intake. Drainage with curettage was performed in standing sedation. The extraction of tooth 308 was deferred. Four months later the fistula recurred. The radiographic examination revealed a split tooth 308 and lesions around its roots (Fig. 5). Previously revealed oblique fracture was not clearly visible. To resolve the problem, it was necessary to remove the fractured tooth by repulsion (Fig. 6). The alveolus was packed with surgical gauze with iodoform. Seven days later polyvinyl siloxane plug (PVS) was inserted. The PVS plug was changed once a week under standing sedation. Four weeks after the procedure, the fistula healed. Additionally, further follow-up information was obtained via telephone calls with the owners.

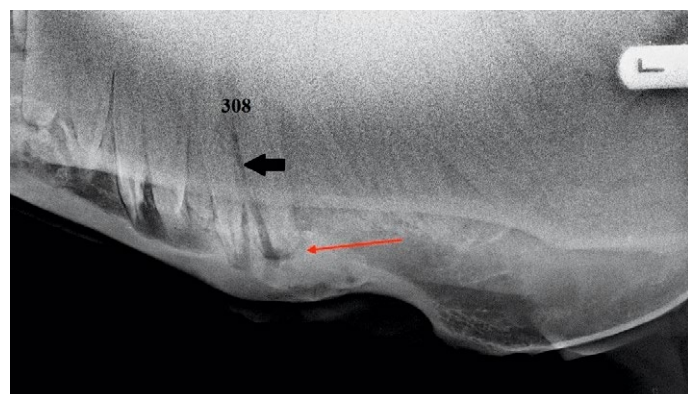


Fig. 5. Radiograph of the mandible in right ventral 60° left-dorsal lateral oblique view (Case 2) with visible fracture line of tooth 308 (black arrow) and callus surrounding the root (red arrow)

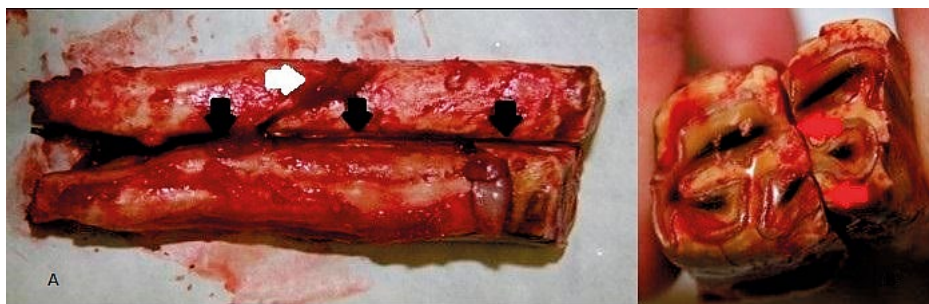

Fig. 6. (A) Lateral view of removed Triadan 308 from Case 2 that has a fracture line running from its occlusal surface to the apical region (black arrows), and oblique fracture in the mesial middle of the reserve crown (white arrow) (B) occlusal surface with fracture line (red arrows)

Results and discussion

External fixation is a well-established method for the treatment of infected, nonunion bone injuries. It has been used to stabilize different bones across the human and animal body (17, 22, 27-29). In equine surgery, external fixators have been mainly described for the treatment of long bone and mandible fractures (9, 25, 26). The presented device is a part of a fixator intended for the osteosynthesis of the III metacarpal bone for which biomechanical analysis was performed (25, 26). The implementation of that type of fixator in the treatment of mandibular body fracture had a satisfying outcome. The advantages of that method included stable reduction of the fracture with minimal additional damage to soft tissues and osseous vascularity; it also provided the opportunity for immediate function return. Application of the fixator did not require extensive surgical dissection and prolonged operating time, removal was easy usually with no need of sedation and the small size of the fixator did not hinder the functioning of the patient. Implants were placed at a distance from the fracture site, which reduced the risk of infection-related complications. In human medicine, a complication of external fixation methods in mandible fracture repair occurs at a high incidence up to 35% (20). Postoperative infections, cellulitis around the pins, nonunion, and malocclusion has been reported. In the presented cases, pin-tract infection occurred in the closest area to the fracture line. Probably it was associated with hematoma and edema occurred due to a fracture which was predisposed to contamination by various types of bacteria. Contamination progressed deeper, following the direction of the implants. The pins involved in the infection area were removed, without a significant impact on the stability of the construction and the healing process. Other possible complications may include damage to the tooth roots. Especially in young animals, the roots and reserve crowns of premolars and molars occupy most of the mandibular body, which significantly increases the risk of tooth damage and reduces the possibility of implant placement. Therefore, intraoperative radiography should be considered mandatory. In both cases teeth were involved in the line of mandibular fractures. Some authors recommend the extraction of teeth located within the fracture line as they may potentially become a source of infection (21). Others suggest that removal of these teeth may lead to secondary distraction of the fracture segments causing problems with stabilization (4). In the presented cases teeth were maintained. In Case 1, the tooth was displaced and luxated, surgical re-position allowed its preservation. In Case 2, the tooth was split for the cranial and caudal part, as the fracture line runs from the occlusal surface to the apical region. There was an additional oblique fracture in the mesial medial reserve crown. Nevertheless, it was decided to leave it in the alveolus

to provide better stabilization during the treatment of the mandible fracture. It was obvious that the tooth is untreatable and will likely become infected causing dental issues. When the dental pulp is exposed by fracture it is immediately infected by oral cavity bacteria, causing pulpitis and ischemia that lead to tooth death. Infection progression varies between the individuals and may take from 12 days to 3 months (6). Clinical and radiological monitoring for evidence of periapical infection along with antibiotic coverage may lead to a satisfying outcome. However, the decision to remove the affected tooth was deferred until the fracture has healed. Ten weeks after the first surgery fistula appeared as expected. The tooth was retained due to the risk of iatrogenic mandibular fracture. The surgery to remove the fractured tooth was performed 6 months after the fixation procedure. Healing was complete within 4 weeks after tooth repulsion. In case 1 an attempt was made to treat the horse using conservative treatment with anti-inflammatory drugs for 10 days without any satisfying outcome. Conservative management has been described as a treatment option for horses with unilateral, stable fractures (12). In clinical examination at the hospital, the wound in the fracture line was contaminated and infected, which was manifested by pain, the inability of food intake, and an unpleasant smell from the mouth. The displaced tooth 309 to the cheek side was probably a direct cause of the disturbed eating. It may be considered that the extraction of tooth 309 would improve the non-surgical management but, on the other hand, it might progress the instability. There was also a possibility to preserve the tooth. To provide rapid stabilization and improve the horse welfare surgical intervention was implemented. The next day after the surgery the patient was reported to eat normally without the need of special diets. Finally we succeeded in preserving the affected tooth 309 in case one.

Compared to the type 2 external skeletal fixation system where the implants are placed perpendicular to the bone surface, the oblique placement makes the stabilization more durable and the contact surface of the implants with the bone is better, which increases its quality. The use of apex pins with a diameter 6 mm and a threaded surface improve significantly the stability of osteosynthesis. The pinless external fixator (PEF) proposed by some authors (9, 14), despite many advantages, has a rather serious disadvantage because of the large size and the possibility of self-damage to elements of the stable equipment. Loosening the clamps is another serious disadvantage. The use of steel plates attached directly to the bone has a high risk of spreading the infection through the implants and destabilization of the fixation (3). Despite some negligible complications, functional fracture healing was achieved. Both horses returned to their previous activities without any clinically apparent masticatory or healing-allied problems at the time of follow-up.

References

1. *Belsito K. A., Fischer A. T.*: External Skeletal Fixation in the Management of Equine Mandibular Fractures: 16 Cases (1988-1998). *Equine Vet. J.* 2010, 33, 176-183, doi: 10.1111/j.2042-3306.2001.tb00597.x.
2. *Bush J. M., Fredrickson R. L., Ehrhart E. J.*: Equine Osteosarcoma: A Series of 8 Cases. *Vet. Pathol.* 2007, 44, 247-249, doi: 10.1354/vp.44-2-247.
3. *Caldwell F. J., Davis H. A.*: Surgical Reconstruction of a Severely Comminuted Mandibular Fracture in a Horse: Severely Comminuted Mandibular Fracture Reconstruction. *Equine Vet. Educ.* 2012, 24, 217-221, doi: 10.1111/j.2042-3292.2011.00264.x.
4. *Cardoso A. S., Mitchell D. F.*: Progression of Pulpitis to Necrosis and Periapical Disease in Deciduous and Permanent Teeth of Monkeys. *J. Dent. Res.* 1971, 50, 934-938, doi: 10.1177/00220345710500042501.
5. *Çeti Nkaya M. A., Demi Rutku A.*: Interfragmental Fixation of Rostral Mandibular Fracture with Cerclage Wire in a Thoroughbred English Horse. *Turk. J. Vet. Anim. Sci.* 2021, 36, 67-71.
6. *Crean S. T., Sivarajasingam V., Fardy M. J.*: Conservative Approach in the Management of Mandibular Fractures in the Early Dentition Phase. A Case Report and Review of the Literature. *Int. J. Paediatr. Dent.* 2000, 10, 229-233, doi: 10.1046/j.1365-263x.2000.00196.x.
7. *Earley E. T., Rawlinson J. E., Baratt R. M.*: Complications Associated with Cheek Tooth Extraction in the Horse. *J. Vet. Dent.* 2013, 30, 220-235, doi: 10.1177/089875641303000404.
8. *Egger E. L.*: Complications of External Fixation. *Vet. Clin. North Am.: Small Anim. Pract.* 1991, 21, 705-733, doi: 10.1016/S0195-5616(91)50080-2.
9. *Haralambus R. M. A., Werren C., Brehm W., Tessier C.*: Use of a Pinless External Fixator for Unilateral Mandibular Fracture Repair in Nine Equids: Mandibular Fracture Repair in Equids. *Vet. Surg.* 2010, 39, 761-764, doi: 10.1111/j.1532-950X.2010.00709.x.
10. *Hatt J.-M., Christen C., Sandmeier P.*: Clinical Application of an External Fixator in the Repair of Bone Fractures in 28 Birds. *Vet. Rec.* 2007, 160, 188-194, doi: 10.1136/vr.160.6.188.
11. *Jansson N.*: Conservative Management of Unilateral Fractures of the Mandibular Rami in Horses: Conservative Management of Mandibular Fractures in Horses. *Vet. Surg.* 2016, 45, 1063-1065, doi: 10.1111/vsu.12561.
12. *Kuemmerle J. M.*: Mandibular Fractures in Horses: Equine Mandibular Fractures. *Equine Vet. Educ.* 2012, 24, 222-224, doi: 10.1111/j.2042-3292.2012.00394.x.
13. *Kuemmerle J. M., Kummer M., Auer J. A., Nitzl D., Fürst A. E.*: Locking Compression Plate Osteosynthesis of Complicated Mandibular Fractures in Six Horses. *Vet. Comp. Orthop. Traumatol.* 2009, 22, 54-58, doi: 10.3415/Vcot-08-01-0001.
14. *Lischer C. J., Fluri E., Kaser-Hotz B., Bettschart-Wolfensberger R., Auer J. A.*: Pinless External Fixation of Mandible Fractures in Cattle. *Vet. Surgery* 1997, 26, 14-19, doi: 10.1111/j.1532-950X.1997.tb01457.x.
15. *Little C. B., Hilbert B. J., McGILL C. A.*: Retrospective Study of Head Fractures in 21 Horses. *Australian Vet. J.* 1985, 62, 89-91, doi: 10.1111/j.1751-0813.1985.tb14146.x.
16. *Ogden N. K. E., Jukic C. C., Zedler S. T.*: Management of an Extensive Equine Juvenile Ossifying Fibroma by Rostral Mandibulectomy and Reconstruction of the Mandibular Symphysis Using String of Pearls Plates with Cortical and Cancellous Bone Autografts. *Vet. Surg.* 2019, 48, 105-111, doi: 10.1111/vsu.12943.
17. *Palmer R. H.*: External Fixators and Minimally Invasive Osteosynthesis in Small Animal Veterinary Medicine. *Vet. Clin. North Am. Small Anim. Pract.* 2012, 42, 913-934, doi: 10.1016/j.cvsm.2012.06.001.
18. *Reif U., Lischer C. J., Steiner A., Fluimlckiger M. A., Auer J. A.*: Long-Term Results of Bovine Mandibular Fractures Involving the Molar Teeth. *Vet. Surg.* 2000, 29, 335-340, doi: 10.1053/jvet.2000.5603.
19. *Rizk A., Hamed M.*: The Use of Cerclage Wire for Surgical Repair of Unilateral Rostral Mandibular Fracture in Horses. *Iran J. Vet. Res.* 2018, 19, 123-127.
20. *Sisk T. D.*: External Fixation. Historic Review, Advantages, Disadvantages, Complications, and Indications. *Clin. Orthop. Relat. Res.* 1983, 15-22.
21. *Spinnato G., Alberto P. L.*: Teeth in the Line of Mandibular Fractures. *Atlas of the Oral and Maxillofacial Surgery Clinics* 2009, 17, 15-18, doi: 10.1016/j.exom.2008.10.006.
22. *Sullins K. E., McIlwraith C. W.*: Evaluation of 2 Types of External Skeletal Fixation for Repair of Experimental Tibial Fractures in Foals. *Vet. Surg.* 1987, 16, 255-264, doi: 10.1111/j.1532-950X.1987.tb00949.x.
23. *Tremaine W. H.*: Management of Equine Mandibular Injuries. *Equine Vet. Educ.* 1998, 10, 146-154, doi: 10.1111/j.2042-3292.1998.tb00869.x.
24. *Turek B., Drewnowska O., Kaplan M.*: External Unilateral Fixator of Own Design for the Treatment of Selected Mandibular Fractures in Horses. *Appl. Sci.* 2019, 9, 2624, doi: 10.3390/app9132624.
25. *Turek B., Potyński A., Drewnowska O.*: Stabilizator zewnętrzny własnej konstrukcji do leczenia złamań trzonu kości śródreżca III u koni. Own-design external fixator for the treatment of diaphyseal fractures of the third metacarpal bone in horses. *Med. Weter.* 2016, 72 (3), 197-202.
26. *Turek B., Potyński A., Wajler C., Szara T., Czopowicz M., Drewnowska O.*: Biomechanical Study in Vitro on the Use of Self-Designed External Fixator in Diaphyseal III Metacarpal Fractures in Horses. *Pol. J. Vet. Sci.* 2015, 18, 323-332, doi: 10.1515/pjvs-2015-0042.
27. *Ugwonali O. F. C., Jupiter J. B.*: Mini External Fixation in the Hand: Tech. *Hand Upp. Extrem. Surg.* 2006, 10, 187-196, doi: 10.1097/01.bth.0000231970.58794.64.
28. *Vogel S. R., Anderson D. E.*: External Skeletal Fixation of Fractures in Cattle. *Vet. Clin. North Am. Food Anim. Pract.* 2014, 30, 127-142, vi, doi: 10.1016/j.cvfa.2013.12.001.
29. *Yardimci C., Ozak A., Nisbet H. O.*: Management of Femoral Fractures in Dogs with Unilateral Semicircular External Skeletal Fixators: Unilateral Semicircular External Skeletal Fixators. *Vet. Surg.* 2011, 40, 379-387, doi: 10.1111/j.1532-950X.2010.00793.x.

**Corresponding authors: Bernard Turek, DVM, DSc, Nowoursynowska 100, 02-797 Warsaw, Poland; e-mail: bernardturek@gmail.com
Natalia Kozłowska, DVM, Nowoursynowska 100, 02-797 Warsaw, Poland; e-mail: Natalia_kozłowska@sggw.edu.pl**